

Mini Review Article

## Contemporary Dental Occlusion in Orthodontics

Fabio Savastano\*

International College of Neuromuscular Orthodontics and Gnathology (ICNOG), Piazza Berlinguer 14, Italy

### Abstract

The controversy on dental occlusion has been an issue since the time dentistry was born. No other definition has been studied and written most then that regarding occlusion. With no doubt, initially, "occlusion" was seen as the result of technical and biomechanical applications: a static relationship of contact between two dental or prosthetic arches. Studies on anatomy of the dental arches and physiology of the stomatognathic system, have contributed to understanding how occlusion develops in a unique fashion for each individual. Nevertheless it's only with the study of the function of the stomatognathic system, along with progress in the development of new diagnostic technological instruments, that we can finally add precious information for a new, more modern definition of dental occlusion.

Specifying an *ideal occlusion* is important because we can extrapolate precious information that could be applied when creating our smiles. The therapeutic information we gather comes as a result from what we define as a malocclusion and it's comparison to an ideal occlusion. Our ultimate goal, be it in general prosthetics or orthodontics, is to get as close as possible to achieving an *ideal occlusion*.

### Introduction

Many efforts have been made to define an ideal occlusion as well as a malocclusion. The fact is that, if we define and speculate on what a malocclusion is, we will get closer to understanding the hidden keys that lie in an ideal occlusion. This is the reason why many publications are about malocclusion even if we do not all agree on what a good occlusion really is. The classification of malocclusions for orthodontists has had them linked to the idea that anything far from a Class I Angle occlusion, and without even one of the six keys of occlusion as stated by Andrews, by end of treatment, is a malocclusion [1, 2]. This mechanical approach does have some obvious benefits for the orthodontist, but it lacks the fundamentals needed to describe occlusion as the final tooth contact of a complex movement of the mandible as it ascends to the upper maxilla. Defining what a good Centric Occlusion is, is definitely not the key to understand if occlusion is a *functional* occlusion. Centric Occlusion is a static representation of maximum intercuspatation and not necessarily represents a good starting point for oral and TMJ functions. The TMJ and muscles do adjust and adapt to changes in dental occlusion for a variety of reasons, such as loss of teeth or decrease in vertical dimension due to tooth wear. This means that the position of CO changes over time, from childhood with the development of dental arches, to adulthood, when other factors linked with age are present.

### The ideal occlusion

The ideal occlusion must be a *functional* occlusion in order to respect function of the TMJ. Research from Gaudy clearly shows that the Temporalis, the Masseter and the Pterygoideus muscles have all direct anatomical connections with the articular disk [3]. This means that when we are including the preservation of TMJ function as one of our objectives for the definition of a *functional* occlusion, we must include the correct function of the muscles attached to the articular disk. These muscles actively participate in the process of adaptation to the changes that occur on occlusion over time, and until they are not overloaded in their duties, they will preserve a good function of the TMJ and the articular disk. The CNS (Central Nervous System) receives afferent inputs by the intra-oral receptors as well as from the TMJ. Once overload for compensation of malocclusion is present, these muscles will start to show signs of fatigue and can alert with exerting pain[4]. This threshold for pain varies in the same individual over time and is linked to biological and anatomical tolerance. An example could be a patient that has never exhibited pain in the TMJ, but the loss of vertical dimension due to posterior loss of a lower molar suddenly results in continuous pain of the joints. The biological and anatomical tolerance of the individual has kept this patient asymptomatic until the anatomic structure has failed to the point where any compensation from the neuromuscular system is impossible. This range of biological and anatomical tolerance is a key factor for the understanding what a *functional* occlusion is. In fact, if we imagine an individual with a large range of tolerance, we should expect that a *functional* occlusion would be that of an occlusion with no TMJ symptoms and good muscle function. If now, for some reason, this range of tolerance diminishes for an acute mental depression, wouldn't the occlusion be the same even if the patient is now symptomatic? This is the reason why we need

\*Corresponding author: Fabio Savastano, M.D., M.Orth., International College Of Neuromuscular Orthodontics and Gnathology (ICNOG), Piazza Berlinguer 14, 17031 Albenga (SV)-ITALY, E-mail: savastano@ICNOG.com

Rec Date: June 30, 2015, Acc Date: July 20, 2015, Pub Date: July 25, 2015.

Citation: Savastano, F. (2015) Contemporary Dental Occlusion in Orthodontics. BAOJ Dentistry 1: 001.

Copyright: © 2015 Fabio Savastano. This is an open-access article distributed under the terms of the Creative Commons Attribution License, which permits unrestricted use, distribution, and reproduction in any medium, provided the original author and source are credited.

to try to identify very specific factors of our ideal occlusion in order to get as close as possible to an ideal *functional* occlusion. Pin pointing the characteristics of an ideal *functional* occlusion seems like a logical process that involves *quality* for functions of the stomatognathic system.

### Muscles and malocclusion

The Masseter, Temporalis and Pterygoideus all participate to mandibular movements. As said above, these muscles are all connected to the particular disk [3]. Surface electromyography has been used for years to assess muscle output and to study the activity of most muscles of mastication [5-11]. This technique is generally used to evaluate the Masseter, Digastricus, Temporalis and Sternocleidomastoideus muscles during mandibular movements and mandibular rest position. It has been observed that in a statistical relevant number of patients with Temporomandibular-Disorder (TMD), overall muscle output during rest position of the mandible is over normal limits. That is, patients with TMD usually have a higher output when muscles are at rest [12]. This is due to the fact that the postural compensation to malocclusion is an effort the muscles exhibit with increase of output to and over a physiological limit. The musculoskeletal system reacts as a protection system to any threat to its own integrity. Another reason for which Surface Electromyography (SEMG) has become popular among researchers is that there is an overall agreement that muscle function of the mandibular postural muscles should be balanced in a normal individual. A unilateral cross-bite will exhibit, during clench, a cross pattern of the total muscle output when muscle groups are compared [13-15]. Various other signs of malocclusion and alteration of head posture can relate to unbalanced muscle SEMG [13, 16, 17]. The sequence of activation during initial tooth contact is another factor studied in SEMG. As the mandible closes, bringing the dental arches to occlusion, any premature dental contact will activate a certain muscle sequence thus leading the dentist to identify the sector or specific tooth responsible of the muscle reaction [18]. The incisor reflex is well avoided where possible, in most malocclusions, resulting in the over-activation of specific mandibular postural muscles during rest position, in order to obtain a "starting point" far from any closing trajectory that would lead to incisor premature contact.

The compensation of malocclusion which results in an adaptive mandibular rest position (AMR or HRP, habitual rest position) will usually secure a close to normal free-way space (1-3mm.) and a trajectory to closure, to CO, with the lowest waist of energy. It would be illogical for the Central Nervous System (CNS) not to compensate the mandibular rest position for a certain malocclusion. This is well known by the orthodontist when he observes a well-compensated skeletal Class III with dental Class I occlusion: the postural adaptation of the head, extension in this case, favors a mandibular trajectory of closure that will avoid as much as possible anterior premature tooth contact. This postural adaptation is the result of a retruded mandible, with the condyle usually located distally and upward in the fossa. Lower arch crowding with lingualized incisors is the result of anterior premature contacts.

In Class II occlusal patients we can experience other factors of compensation. Deep-bite and excess over-jet (OJ) may usually show increased freeway space during HRP. A closer look at the shapes of the dental arches will show an excess curve of Spee that accommodates the tongue bilaterally. Interesting to say, that the resulting free-way space between the tongue and upper arch is often about 2mm. with the tongue acting like an artificial bite. The consequence of excess OJ is an abnormal swallow pattern in which the patient does not come to CO during deglutition but swallows with tongue between the teeth.

All orthodontists have experienced TMJ sounds of some patients at end of treatment that were not present with the initial malocclusion. No orthodontic treatment can be perfect to pin point the ideal occlusion in all of its peculiarity, but avoiding to acknowledge the changing trend in treatment planning and gnathology, may lead the orthodontist to continue to treat their patients mechanically and without respect of function.

### Functional occlusion

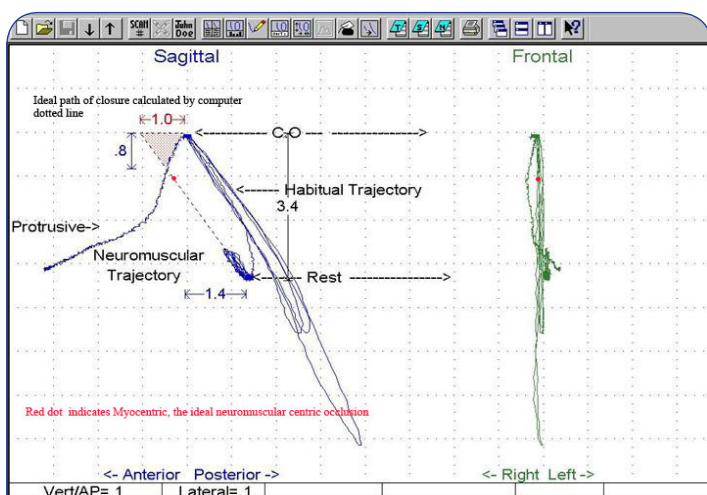
Besides the characteristics most orthodontists believe are important for a good occlusion, that is, OJ-OB-Curve of Spee and Wilson, occlusion Class, disclusion and canine guidance, we must add more information to define a *functional* occlusion, which is far from any static description of it. Dynamic representation of mandibular movements with Mandibular Kinesiographs (CMS, computerized mandibular scanning) has disclosed some precious information regarding function of the stomatognathic system. There is no doubt that this inestimable information has been ignored by dentists for quite some time. As CMS made the way in Dental Faculties over the world, the scientific community started to add and somewhat change their knowledge on occlusion.

The anatomy of the dental arches requires an helicoidal plane of occlusion [19], perhaps this view of the anatomic relation of the dental arches is sufficient to undermine any pure mechanical interpretation of occlusion. This is because an helicoidal development of the dental arches is the evolutionary result specific functions, swallow, mastication and tooth wear [20]. In order to satisfy the *functional* demand of the masticatory system, teeth, muscles and TMJ accommodate into their range of tolerance. Each single component participates to the requests from the CNS to maintain basic functions as swallow, speech and mastication. This accommodative response is the answer to the alteration of the ideal relationship between the upper maxilla and the mandible. The result is what we see more easily, that is, a malocclusion. We are focusing on one element of our chain and forgetting to focus on the other elements that also participate to this compensation, TMJ and muscles.

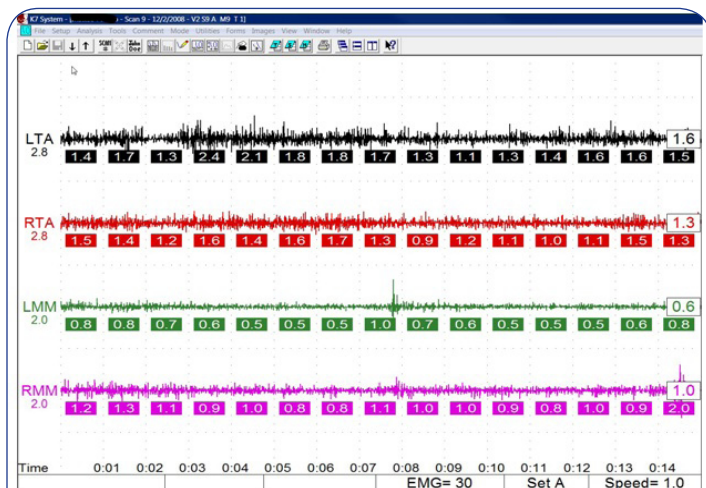
Every component of this chain, TMJ-muscles-teeth, has different limits of adaptation, of tolerance. Some patients will exhibit TMJ pain while others may break teeth or crowns and some may just have crooked teeth. Generally, the locus minoris resistentiae fails first because it has a smaller range of tolerance. Deep-bite patients with large condyles and condylar fossa have usually a large range of tolerance when compared to open-bite patients, with little free-

way space and thin condyles. On the other hand, malocclusion can be the result in a patient suffering from TMJ pain with signs of internal derangement [21]. Patients that have history of TMD are more likely to relapse with any occlusal change [22]: they are border line patients with a very small range of tolerance.

So how do we record an ideal mandibular-maxillary relation? Dentists have been, for quite some time, using bites or other strategies to distract the CNS from knowing where the mandible lays in order to relax muscles and record a better working Centric. Avoiding inter-arch tooth contact, interrupts most if not all, the afferent stimuli from the periodontal ligaments to the CNS. This is usually done with occlusal wax, even if there are other very effective methods such as the Aqualizer® [23]. As a response, the CNS does not act peripherally on the muscles of mandibular posture. Muscles do relax and a new mandibular rest position is obtained: a deconditioned rest position (RP). Recording this rest position by means of intra-oral silicone will give us an ideal mandibular-maxilla relationship, but will not show us the ideal mandibular trajectory to CO. For this reason, neuromuscular dentists use a low frequency Transcutaneous Electrical Nerve Stimulator (TENS) that helps relax muscles during afferent stimuli interruption. When adequately adjusted to pulse at higher output, this device will create a mandibular movement on a neuromuscular trajectory [10, 11, 24-26]. This can be easily visualized via the CMS that can calculate the ideal path of closure to a new CO, Fig 1. There is no better way to test if muscles are relaxed than that of surface electromyography, Fig. 2. A new CO is calculated at about 2 mm. vertical from rest position on the neuromuscular trajectory. This new centric occlusion is called the Myocentric and is certainly the best static interpretation of a functional occlusion [27]. It should be used as our primary objective for final occlusion.



**Fig 1.** Sagittal and frontal view of mandibular movements from rest position (RP) to centric occlusion (CO) after relaxation of postural muscles. The Neuromuscular Trajectory represents the ideal path of closure to the horizontal plane of occlusion. The Myocentric is calculated on the ideal path of closure.



**Fig.2** Example of surface EMG. Several muscles can be tested with surface electromyography. Here Left and Right Temporalis ( LTA-RTA) and Left and Right Masseter (LMM-RMM) muscles are tested.

### Conclusions

Defining and achieving a final dental occlusion for our patients is the key factor we base our treatment plans on. *Functional* analysis plays an important role for the identification of a neuromuscular relationship of the jaws and should be taken in consideration for complex rehabilitations and orthodontic cases with TMJ dysfunction.

This procedure takes some effort and time, therefore patient selection is not an option. These modern technical procedures have disclosed precious information for the comprehension of dental occlusion and function of the stomatognathic system. A *functional* occlusion respects the ideal function of muscles-TMJ and teeth without any exception. It is the result of a *functional* analysis and not the calculus of Cephalometrics.

### References

1. Salzmann JA (1965) The Angle Classification as a Parameter of Malocclusion. Am J Orthod. 51: 465-466.
2. Andrews LF (1972) The six keys to normal occlusion. American journal of orthodontics 62(3): 296-309.
3. Bravetti P, Membre H, El Haddioui A, Gerard H, Fyard JP, et al. (2004) Histological study of the human temporomandibular joint and its surrounding muscles. Surg Radiol Anat 26(5): 371-378.
4. Okeson JP (1985) Signs and symptoms of temporomandibular disorders, in Fundamentals of occlusion and temporomandibular disorders JP Okeson Editor Mosby: St. Louis. p. xii 500 p.
5. Wozniak K. et al. (2013) Surface electromyography in orthodontics - a literature review. Med Sci Monit 19: 416-23.
6. Castrolforio T, Bracco P, Farina, D (2008) Surface electromyography in the assessment of jaw elevator muscles. J Oral Rehabil 35(8): 638-645.
7. Hugger A, Hugger S, Schindler HJ (2008) Surface electromyography of the masticatory muscles for application in dental practice. Current evidence and future developments. Int J Comput Dent 11(2): 81-106.

8. Hugger S, Schindler HJ, Kordass B, Hugger A, et al. (2013) Surface EMG of the masticatory muscles (Part 3): Impact of changes to the dynamic occlusion. *Int J Comput Dent* 16(2): 119-123.
9. Monaco A, Cattaneo R, Spadaro A, Giannoni M, et al. (2008) Surface electromyography pattern of human swallowing. *BMC Oral Health* 8: 6.
10. Schindler HJ, Blaser W (1982) [T.E.N.S., a myofunctional concept for oral rehabilitation]. *Quintessenz* 33(11): 2181-91.
11. Schindler HJ, Blaser W, Rath E (1982) [T.E.N.S. (transcutaneous electroneurostimulation), a myofunctional concept for oral rehabilitation (II)]. *Quintessenz* 33(2): 295-307.
12. Parker MW (1990) A dynamic model of etiology in temporomandibular disorders. *J Am Dent Assoc* 120(3): 283-90.
13. Andrade AS, Gavião MB, Derossi M, Gameiro GH (2009) Electromyographic activity and thickness of masticatory muscles in children with unilateral posterior crossbite. *Clin Anat* 22(2): 200-206.
14. Andrade Ada S, et al. (2010) Characteristics of masticatory muscles in children with unilateral posterior crossbite. *Braz Oral Res* 24(2): 204-210.
15. Wozniak KL, Szyszka-Sommerfeld, Lichota D (2015) The electrical activity of the temporal and masseter muscles in patients with TMD and unilateral posterior crossbite. *Biomed Res Int* 2015: 259372.
16. Bergamini M, Pierleoni F, Gizdulich A, Bergamini C (2008) Dental occlusion and body posture: a surface EMG study. *Cranio* 26(1): 25-32.
17. Miralles R, Gutierrez C, Zucchini G, Cavada G, Carvajal R, et al. (2006) Body position and jaw posture effects on supra- and infrahyoid electromyographic activity in humans. *Cranio* 24(2): 98-103.
18. Cooper BC (1997) The role of bioelectronic instrumentation in the documentation and management of temporomandibular disorders. *Oral Surg Oral Med Oral Pathol Oral Radiol Endod* 3(1): 91-100.
19. Smith BH (1986) Development and evolution of the helicoidal plane of dental occlusion. *Am J Phys Anthropol* 69(1): 21-35.
20. Spears IR, Macho GA (1995) The helicoidal occlusal plane - a functional and biomechanical appraisal of molars. 1995: Proceedings of the 10th International Symposium on Dental Morphology. At Berlin 391-397.
21. Plesh O, Stohler CS (1992) Prosthetic rehabilitation in temporomandibular disorder and orofacial pain patients. Clinical problem solving. *Dent Clin North Am* 36(3): 581-589.
22. Le Bell Y, Jamsa T, Korri S, Niemi PM, Alanen P (2002) Effect of artificial occlusal interferences depends on previous experience of temporomandibular disorders. *Acta Odontol Scand* 60(4): 219-222.
23. Lerman MD (1974) The hydrostatic appliance: a new approach to treatment of the TMJ pain-dysfunction syndrome. *J Am Dent Assoc* 89(6): 1343-1350.
24. Donegan SJ, Carr AB, Christensen LV, Ziebert GJ et al. (1990) An electromyographic study of aspects of 'deprogramming' of human jaw muscles. *J Oral Rehabil* 17(6): 509-518.
25. Kamyszek G, Ketcham R, Garcia R Jr, Radke J et al. (2001) Electromyographic evidence of reduced muscle activity when ULF-TENS is applied to the Vth and VIth cranial nerves. *Cranio* 19(3): 162-168.
26. Monaco A, Cattaneo R, Spadaro A, Marzo G et al. (2008) Neuromuscular diagnosis in orthodontics: effects of TENS on the sagittal maxillo-mandibular relationship. *Eur J Paediatr Dent* 9(4): 163-169.
27. Neuromuscular dental diagnosis and treatment: Robert R. Jankelson Ishiyaku EuroAmerica, St. Louis: 1990. 687 pages, 1132 illustrations.